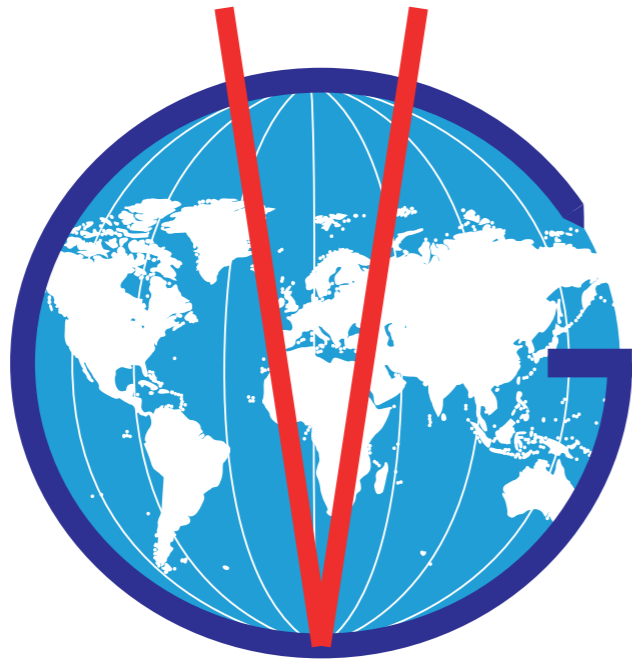


VETLIG GLOBAL



The free fibers for the respect of biology

ACHILLES TENDON RECONSTRUCTION

Achilles tendon reconstruction technique using the STIF
implant - Vetlig Global™

Dr J.P. LABOUREAU

IMPLANTS:

STIF - Vetlig Global™ has developed a synthetic tendon for the reconstruction of the Achilles tendon in dogs, in an efficient and reliable way for the veterinarian, and non-traumatic for the animal and its owner.

However, its use is not limited to the reconstruction of the Achilles tendon, i.e. reconstruction of all tendon ruptures (patellar tendon, quadriceps tendon, etc.).



Two models are available:

- The CAT 32/20 tendon:

Composed of 32 fibers (resistance 3 900 N) for animals under 20 kg. It requires a calcaneal tunnel with a diameter of 3.6 mm as well as an interference screw of variable diameter according to bone density (generally 4 mm).

- The CAT 48/25 tendon :

Composed of 48 fibers (resistance 6 000 N) for animals over 20kg. It requires a calcaneal tunnel with a diameter of 4.2 mm as well as an interference screw of variable diameter according to bone density (generally 4.5 mm).

Note: The choice of ligament and tunnel diameter depends not only on the weight of the animal but also on the size of the calcaneus.

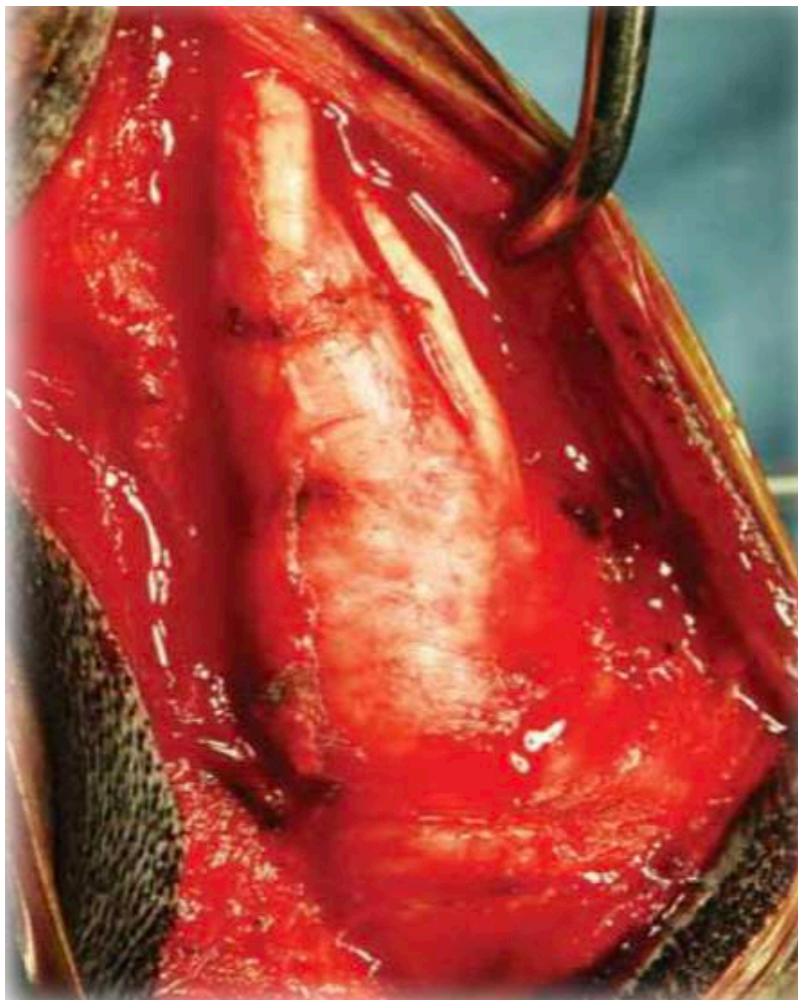Surgical technique

The surgical technique is applied here on a normal canine cadaver, allowing a clear identification of the anatomical characteristics.

Step 1: Incision

A posterolateral incision is made, extending from the gastrocnemius muscle to the insertion of its tendon on the calcaneus. The area of recent or old rupture will be easily identified.

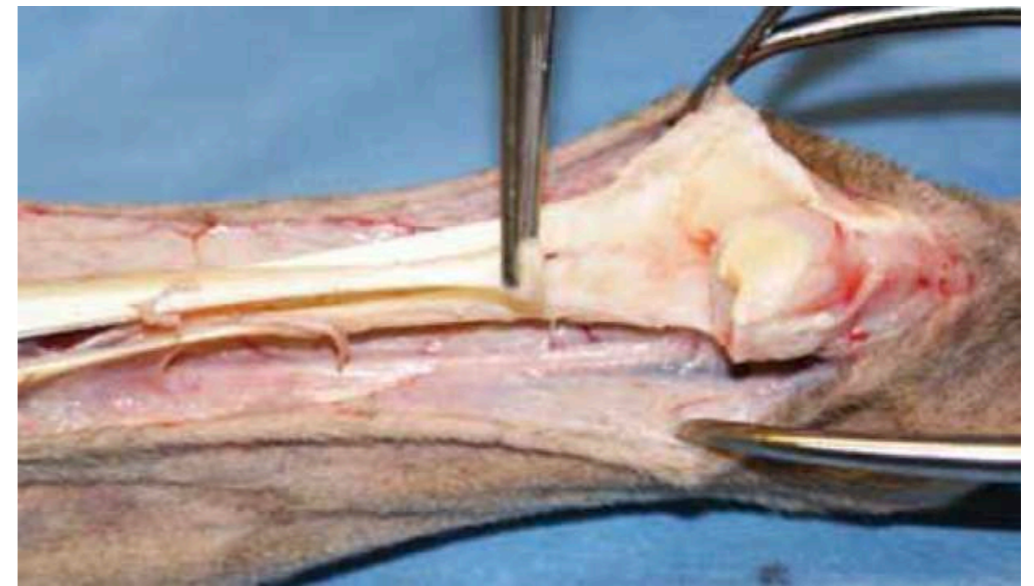
In the clinical case below, the thickened insertion of the tendon is visible at the base of the image.



Step 2: incision of the tendon sheath

The tendon sheath is incised; it is often difficult to differentiate the combined insertions of the gastrocnemius and tendon from the gracilis, the femoral biceps and the semitendinosus.

The lateral retinaculum of the superficial digital flexor tendon is incised along the lateral margin of the calcaneus and dislocated. In the image below on a cadaver, the tendon has been sectioned.



In the majority of cases, part of the hyperplastic scar tissue must be excised but sufficient fibroblastic tissue must be left to cover the synthetic fibres.

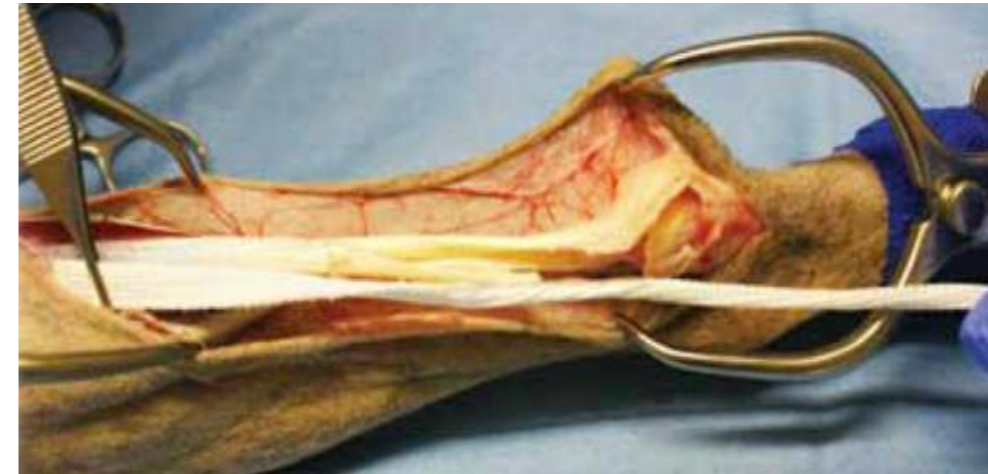In the case of a chronic lesion with retraction of the proximal portion, tenolysis, dissection and cutting of the adhesions should be performed to regain maximum length.

Step 3: Placement of the proximal part of the implant.

The STIF CAT 32/20 or 48/25 implant is placed on the calcaneal common tendon to estimate the optimal positioning. The proximal flat portion of the synthetic tendon is positioned in the way that the free fibers are located in the area of the tendon rupture, no free fibers should enter the calcaneal tunnel.

The proximal portion of the ruptured tendon is incised with the scalpel in a frontal plane, including up to the myotendinous junction. The proximal part of the synthetic implant will be slid "sandwiched" into the space thus created and will be fixed by about ten stitches of non-absorbable thread taking up the tendon tissue and the synthetic tissue.

The proximal part of the synthetic tendon can be shortened if necessary according to the available tendon length (for this purpose the synthetic fibres must be cut off above the transverse stop points).



Step 4: Placement of the disc portion of the implant

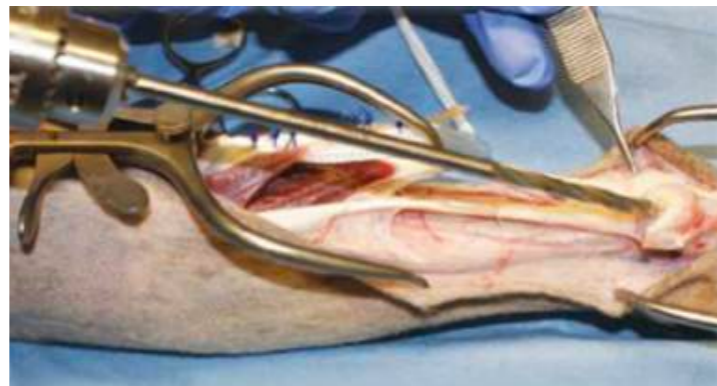
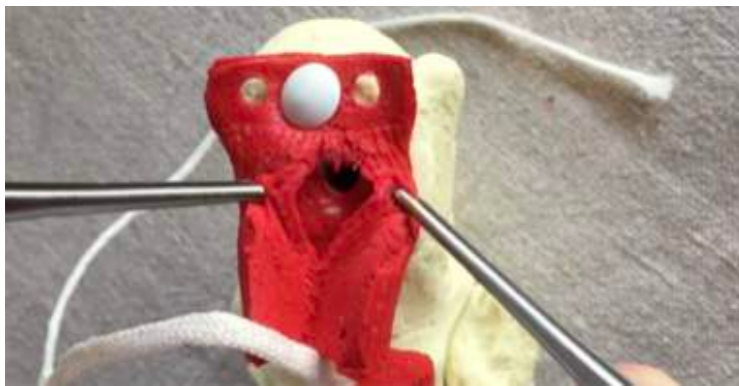It is important to remember that the implant and the gastrocnemius will be pulled distally towards the calcaneus to restore functional length, so the implant must be fixed proximally enough so that the free fibers do not enter the calcaneal tunnel.

The incision in the proximal tendon through which the synthetic reinforcement was slid is closed with an overjet of fine resorbable thread.

To ensure optimal positioning, it is advisable to drill a pilot tunnel with a 2 mm Kirchner wire.

A blind tunnel is then drilled 25 to 30 mm deep from the centre of the tuberosity in the axis of the calcaneus with the appropriate cannulated drill bit.

The surface of the posterior tuberosity slopes slightly towards its inner edge. It is important to evaluate this on preoperative radiographs and visually intraoperatively to ensure that the drilling angle is correct, otherwise the drill may exit onto the lateral or medial cortex of the calcaneus.



The distal part of the implant is bent longitudinally in half. The stifle can be bent to facilitate insertion. The distal part of the implant is pulled to bring the proximal and distal parts of the tendon as close together as possible and the tension is adjusted to allow dorsal flexion of the hock when the stifle is in flexion and to allow very little when the stifle is in extension.



The implant, folded in half, is then brought to coincide with the entrance of the tunnel and pushed to the bottom with a 2mm pin at the end. The pin is left in place and checked for correct tension. If not, it is adjusted.

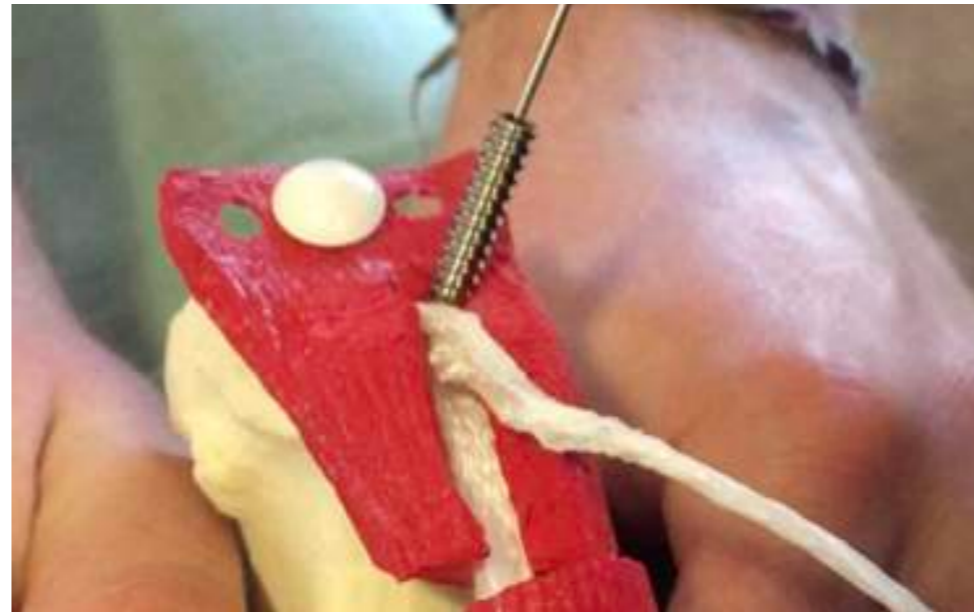

Notes: In most cases, some hyperplastic scar tissue must be excised but enough fibroblastic tissue must be left to cover the synthetic fibers.

In the case of a chronic lesion with retraction of the proximal portion, tenolysis must be performed, dissecting and cutting the adhesions to regain maximum length.

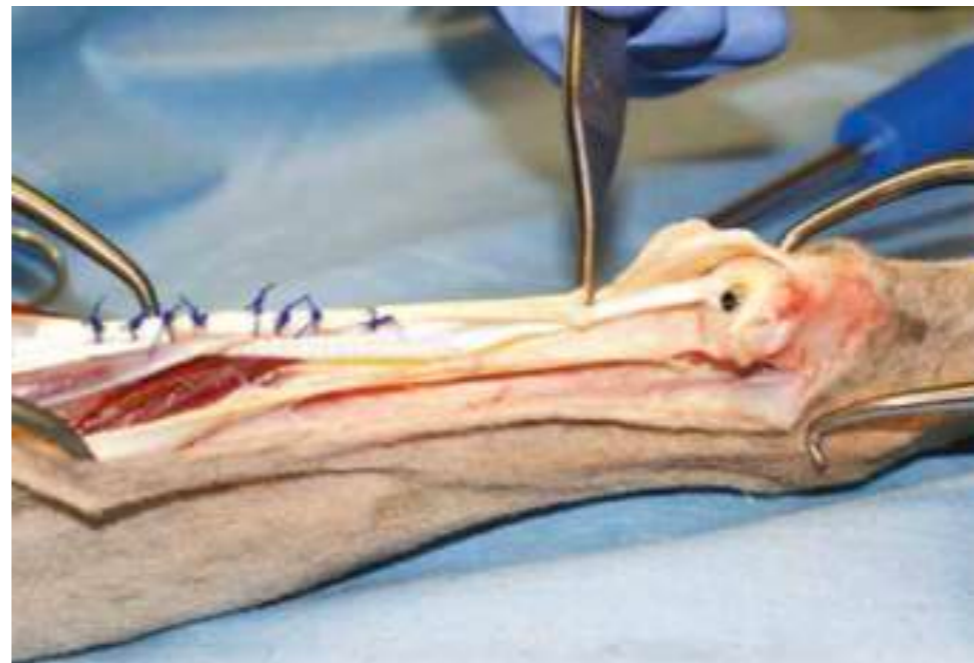Step 5: Insertion of the screw in the tunnel

Once the tension has been determined, the Kirchner pin is replaced by an interference screw guided by a 2.5 mm hexagonal pin for 5 mm screws using the female screwdriver, or by a 1 mm pin for 4 mm or 4.5 mm screws using the cannulated hexagonal screwdriver.



The repair is completed by 1 or 2 frame lacings to perfect the facing of the edges of the break.

The superficial digital flexor tendon dislocated at the beginning of the operation is reduced, the tendon sheath is closed. The wound is closed plane by plane.



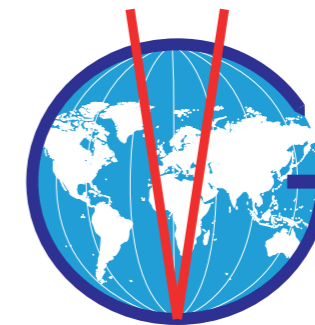Post-operative care:

- For the first 48 to 72 hours, a back splint, incorporated into a padded dressing, is applied to reduce post-operative swelling.
- The same large bandage with back splint is maintained for 5 to 6 weeks and allows partial support under control.
- Follow-up x-rays are taken at six weeks to assess the position of the screw.

NOTE:

- The size of the calcaneus determines the use of CAT 48/25 or CAT 32/20.
- In smaller animals it is possible to use the STIF CCL 24 /15 ligament which requires only a 3mm tunnel, which is laced through the proximal tendon and fixed in the calcaneus with a 3.5mm or 4mm diameter screw.

VETLIG GLOBAL





VETLIG GLOBAL is a commercial trade mark of STIF SAS

Société par actions simplifiées au capital de 375 530 €

Head office : 651 C Chemin de la Martourette

06530 Le Tignet

France

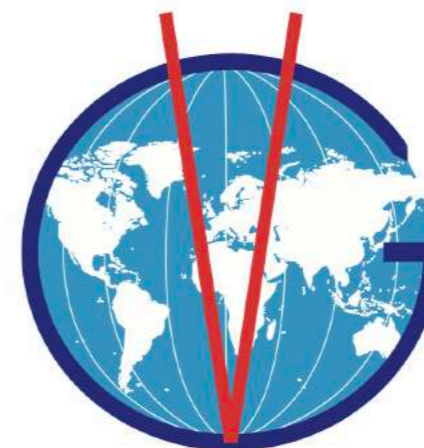RCS n° 522 917 939 - Grasse

SIRET : 522 917 939 00038

Intracommunity VAT number: FR 86 522 917 939

Code APE : 7219Z

VETLIG GLOBAL



Email : contact@vetlig-global.com

-

leo.brunel@vetlig-global.com

Tel : +33 (0)6 34 36 79 69

-

romain.gaucher@vetlig-global.com

Tel : +33 (0)6 84 09 60 67

STIF - Vetlig global is partner of



and

