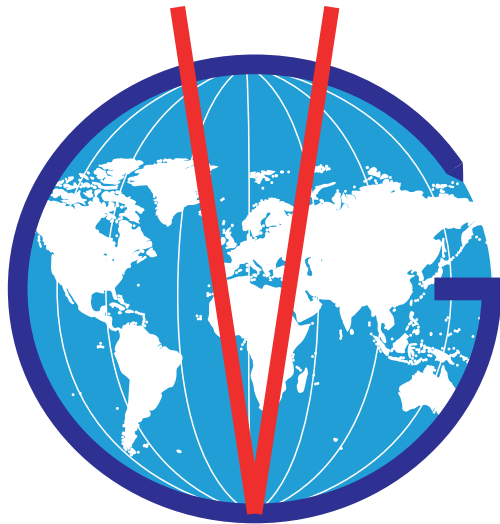
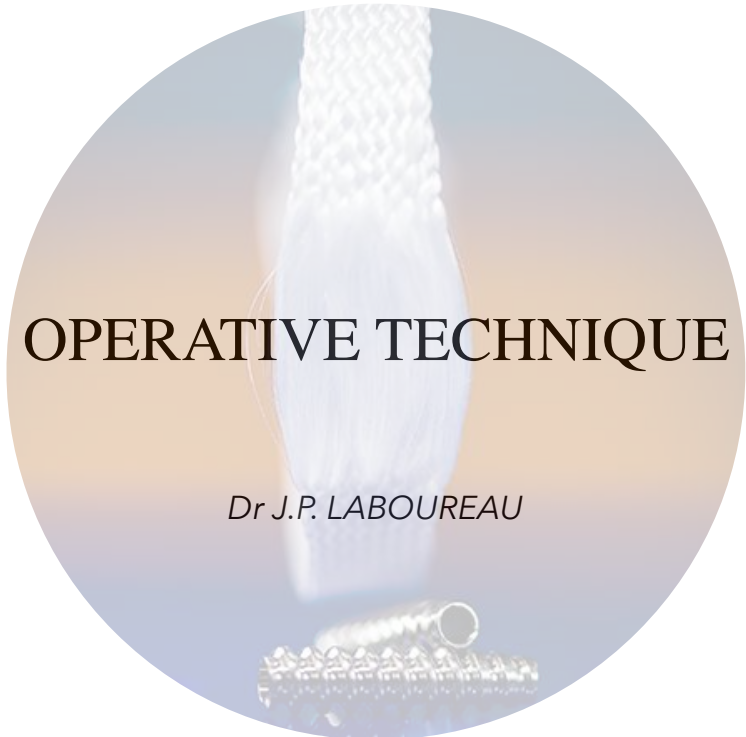

VETLIG GLOBAL




The free fibers for the respect of biology

RECONSTRUCTION OF THE CAUDAL CRUCIATE LIGAMENT



THE CHOICE OF LIGAMENT DEPENDS ON THE ANIMAL'S WEIGHT AND ACTIVITY.



WEIGHT	LIGAMENT
5 - 8 kg	16 fibers/ 10mm free fibers
8-12kg	24 fibers/ 15mm free fibers
12-25kg	32 fibers/ 17mm free fibers
+ 25kg	48 fibers / 19/22/25mm free fibers

Note:

For the 48 fibers ligament, the length of the intra-articular fibers is determined intra-operatively according to the length of the original ligament estimated with a scaler (intra-articular distance between the entrances to the tibial and femoral tunnels).

Introduction

Diagnosing caudal cruciate ligament rupture

Studies on ruptures of the caudal cruciate ligament (CaCL) and their treatment are poor compared to those on the cranial ligament.

However, these ruptures do exist but appear to be rarely diagnosed. They are often discovered during surgical exploration for a diagnosis of a cranial cruciate ligament injury in front of an anterior drawer which is in fact only the correction of a posterior drawer (Fig1). The difference is sometimes difficult if care is not taken to note the recoil of the tibial tuberosity.

The best arbiter is profile radiography, which allows the tibial plateau recoil to be seen and measured.

Whether they are isolated or associated with other lesions (CrCL or multiple lesions during stifle dislocation), lesions of the CaCL are rarely the subject of specific surgical treatment. Since there is no officially recognised effective treatment, it is easy to claim, as was the case in the past for cranial cross lesions, that they are well tolerated. What is called a conservative treatment is adopted, which effectively preserves the posterior subluxation of the tibia.

To the credit of veterinary surgery it must be said that the same has been true in human surgery where the interest in lesions of the CaCL dates back less than forty years, when it appeared that they were far from being insignificant. While the functional disorders are perhaps less spectacular in terms of instability, the consequences on biomechanics and early degenerative lesions are major.

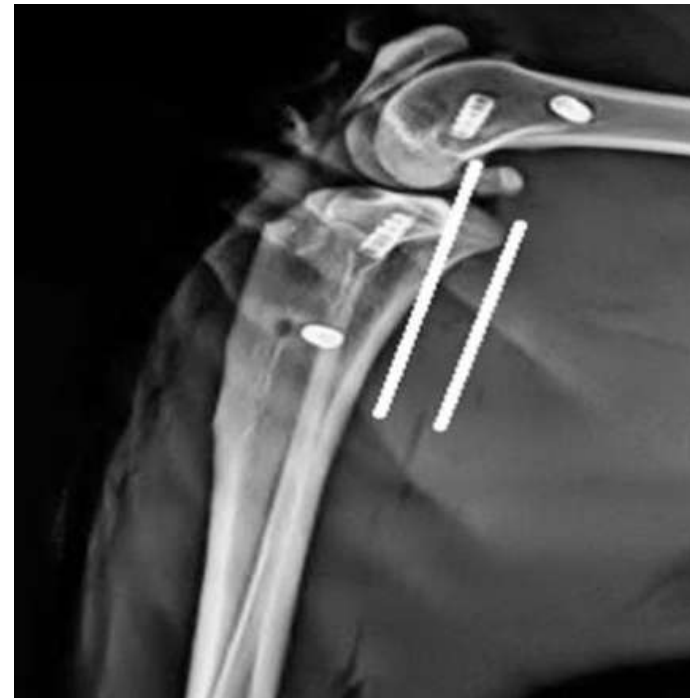
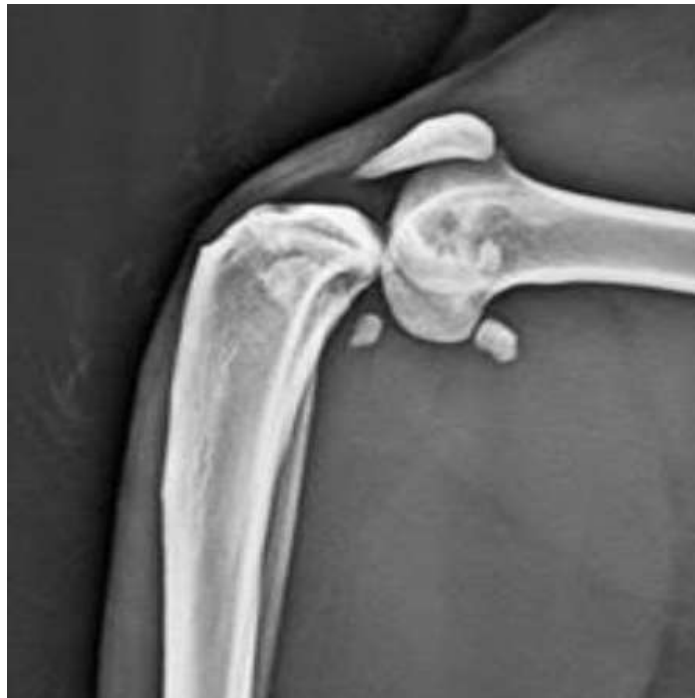
Fig. 1 - Typical example: dislocation of the stifle in a 10kg cat; the lesion of the 2 crossed cats is obvious; the lesion of the CaCL is recognised surgically but only the CrCL is repaired by intra-articular plasty: the insertion of the CrCL plasty causes the tibia to move backwards, which is fixed in the caudal position.


Use of the tibial guide for placement

The operation is performed anteriorly without any posterior approach by medial para patellar arthrotomy or arthroscopy.

The spatula of the guide is inserted into the intercondylar notch, passing inwards of the cranial cross to be inserted flush with the bone behind the popliteal surface of the tibia, where the CaCL is inserted.

First, the pointed drill is placed on the guide (to avoid slipping on the cortex) to safely drill an ascending tunnel at an angle of about 45° from the medial side of the metaphysis to the retro tibial surface where it comes to rest on the spatula which completely protects the vascular-nervous bundle.

This first drill is then replaced by the straight tip drill which allows the retro tibial exit of the tunnel to be well clear, and then by a tube into which a metal loop is pushed, which comes out at the upper end of the cannulated spatula stem. The guide is withdrawn, leaving the metal loop in place to pull the ligament through the tibial tunnel.



Step 1: installation and approach

The animal is installed supine, if possible in a U-shaped cushion to ensure a stable position.

A medial para-patellar incision is made from the tibial metaphysis to the upper edge of the patella. This incision can be enlarged a little, especially upwards on the thick stifles, passing inwards through the vastus medialis.

Complete exploration of the joint allows treatment of possible meniscal lesions and removal of possibly troublesome osteophytes.

It is essential to resect the infra patellar fat pad and all fibrous tissue in order to get a good view of the notch and its contents.

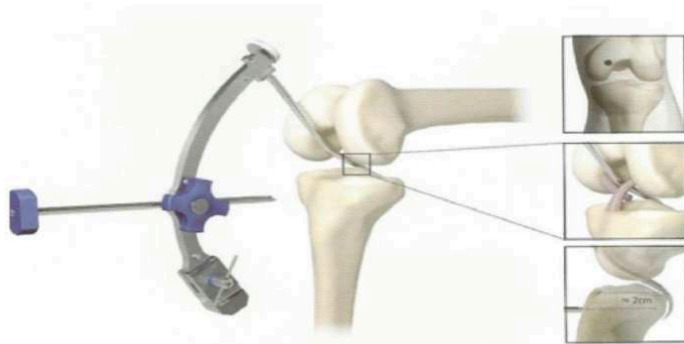
The first step in old lesions is to dissect the healed CaCL with fine scissors (Metzenbaum type) and individualise the CaCL, which is often attached to the CrCL. Following the anterior aspect of the CaCL, the scissors cut all tibial ligament and capsular adhesions and insertions over a width of 1 - 2 cm.

Fig. 2 - Tibial guide with its various components: pointed drill, straight cannulated drill, wire guide tube. Detail of the retro tibial spatula with metal loop and exit of this loop through the shank of the spatula.

Step 2: Drilling the tibial tunnel

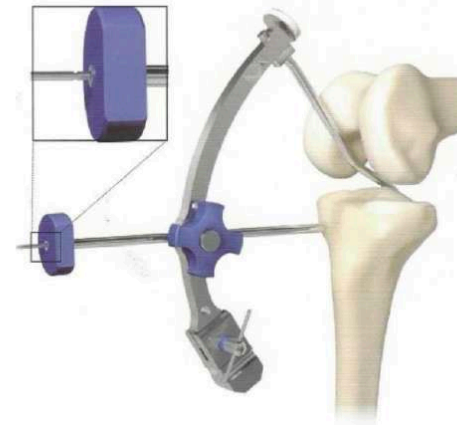
The spatula of the sight is inserted into the notch, free of osteophytes if necessary.

The spatula passes to the medial edge of the cranial cruciate ligament. It is inserted until its shaft is in contact with the roof of the notch and the sliding anterior fixation rod parallel to the tibial plateau.



The guide spatula is inserted into the intercondylar notch through the Crcl and down behind the tibial plateau.

It is oriented inwards from the median line and in such a way that the point of penetration of the drill bit is located in the middle of the inner face of the metaphysis. As the orientation of the spatula is chosen, this position can be secured by inserting a Kirschner wire into the cannulated sliding shank.



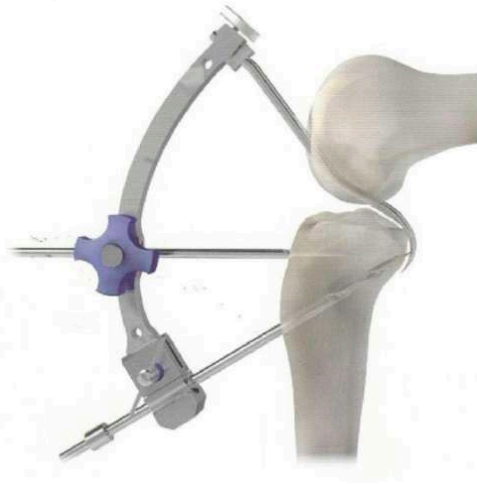The position of the guide is stabilized by a pin parallel to the tibial plateau.

Note: If the initial skin incision is not sufficient, a counter-incision can be made, centred on the point of penetration of the drill bit, up to the cortex, which is exposed with a rugine, outwards to the patellar tendon and inwards. A skin bridge is thus created between the arthrotomy incision and this counter-incision.

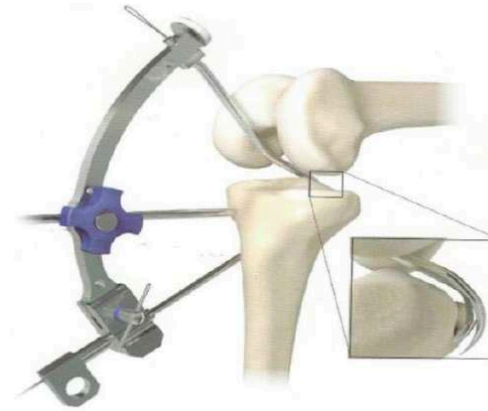
It is in fact at this level, in the patellar tendon, and then at the foot of the anterior cruciate ligament, that the terminal nerve branches of the long saphenous nerve arrive, which it is preferable to respect (proprioceptive fibres and skin sensitivity).

The pointed drill is used first and will pierce the tibial tunnel until contact is made with the posterior spatula.

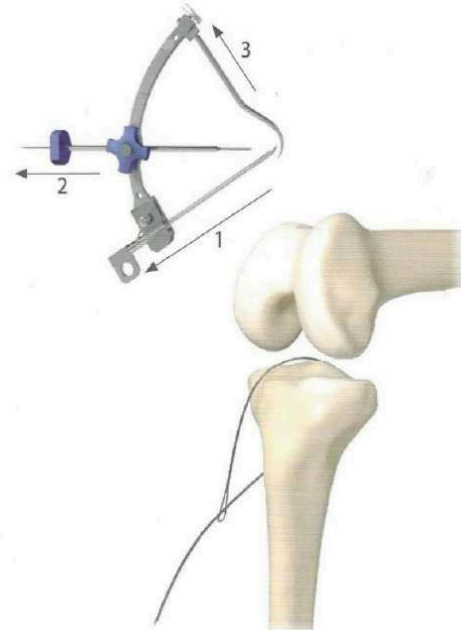
This first drill is replaced by the straight-tipped drill, which is passed several times to clear the bone chips in front of the spatula.



Le tunnel tibial est percé à 45° avec le foret pointu depuis la métaphyse médiale jusqu'à buter contre la spatule. Le foret à bout droit complètera ce percement pour enlever les débris osseux qui pourraient gêner le passage du ligament.



The tube slightly raised at its end replaces the drill in the guide and allows the metal loop to pass over the spatula. The metal loop goes up in front of the spatula.



The tube passes wire is removed, then the fixing pin, then the whole guide with the spatula. This brings the metal loop which is grasped and placed on a clamp.

Step 3: femoral tunnel

The tunnel is drilled directly with a pointed drill from the selected point on the axial side of the well exposed medial condyle by bending the knee beyond 90° and dislocating the patella.

In no case should the tunnel be transverse and perpendicular to the diaphyseal axis, but on the contrary should approach this axis. This reduces the torsional stress on the plasties.

The femoral tunnel is catheterised through a tube. A metal loop is passed through this tube from top to bottom.

Note:

The correct positioning of the femoral tunnel is essential. The femoral insertion of the posterior cruciate femur, studied by Ogata et al., shows that there is a practically isometric area between the two main bundles corresponding to the centre of the insertion.

The centre of the anatomical insertion of the CaCL corresponds to a point which can be geometrically defined for each knee as 40% of the length of a straight line parallel to the Blumensat line and starting from the most prominent point of the posterior condyle. This point corresponds to the centre of the insertion which is the most isometric area as shown below:

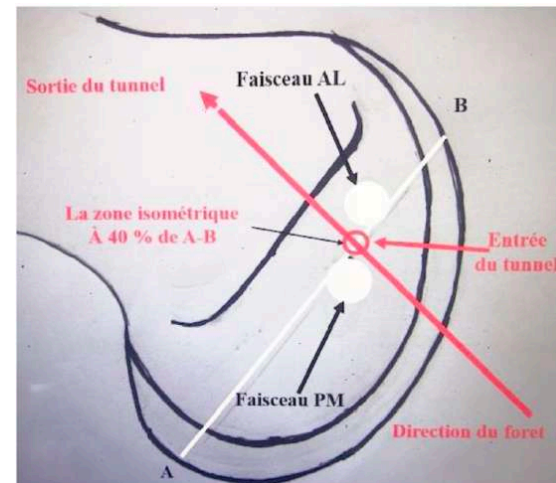
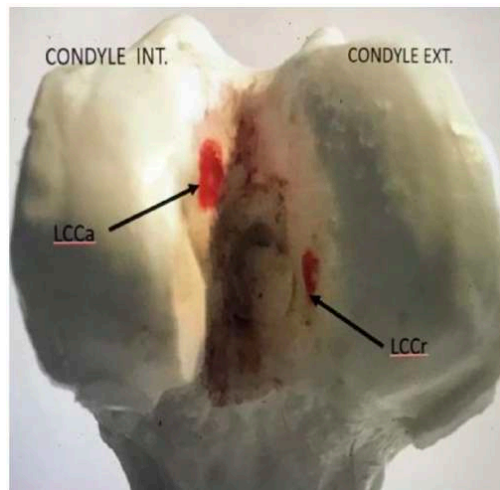


Fig. 3 - left: The drilling areas of the CaCL and CrCL tunnels.

Right: Insertion of the PCL on the axial side of the medial condyle and correct positioning of the drill at the isometric point for the trans-condylar tunnel.

Step 4: Ligament passage and femoral fixation

It is easier to first pass the ligament through the tibia from the bottom up, from the internal metaphyseal cortex of the tibia to the joint. To do this, a second loop is introduced into the initial loop, which is drawn through the tibia from top to bottom so that the loop emerges from the tibial metaphyseal cortex to pass the ligament from bottom to top (Fig. 4).

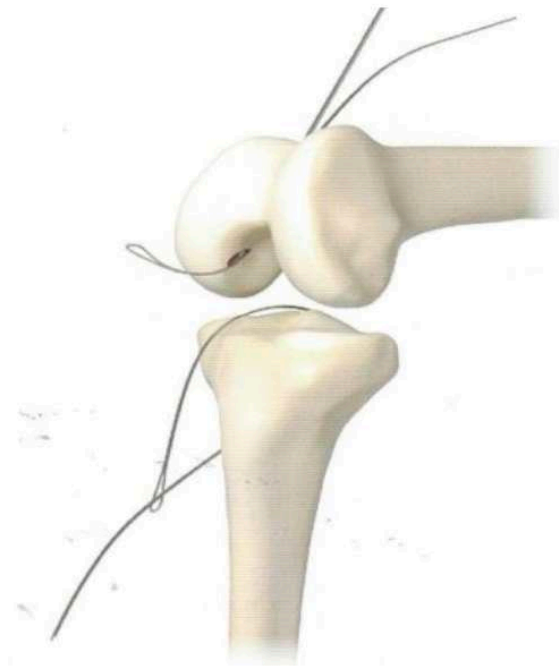


Fig. 4 - The 2 metal loops in place for passage of the ligament.

The free fibres in the joint must be adjusted and then the ligament must be passed through the medial femoral condyle from bottom to top.

The ligament on the femur side is fixed with 2 interference screws as shown in the diagram below, one in the trans-condylar tunnel, the second in an overlying transverse tunnel by tightening the transplant. This double fixation is necessary in view of the stresses which will be exerted.

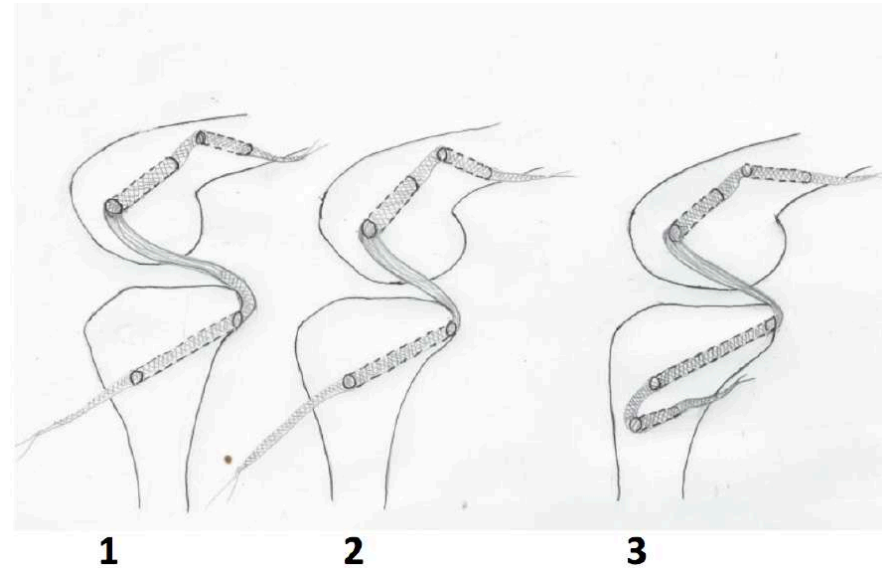


Fig. 5 - Pulling on the distal end of the implant (2) ensures correction of the posterior tibial subluxation and re-centring of the stifle, which is indicated by re-tensioning the CrCL if it is an isolated lesion of the CaCL.

Step 5: Tension adjustment and tibial fixation

After correction of the rear drawer the stifle is successively flexed - extended to check that the tension allows full mobility.

This correct position is fixed by inserting a first screw in the primary tunnel.

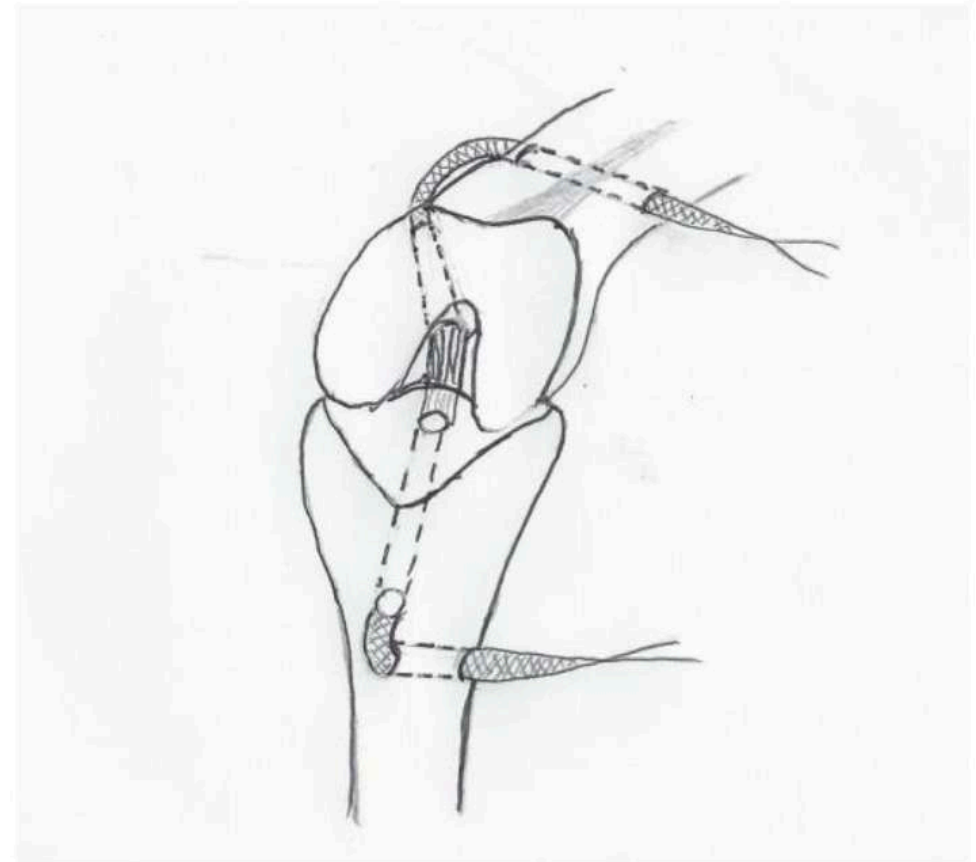
As the forces exerted on the plasty are considerable, it is essential to complete the primary fixation with a second screw in an underlying transverse bone tunnel, perpendicular to the axis of the diaphysis as shown in the diagram opposite.

The length of the ligament thus preserved outside the femoral and tibial primary bone tunnel will also allow it to be recovered if it is needed one day, for re-tensioning, a new accident or any other indication.

The ends of the ligament are cut flush with their exit from the transverse tunnels.

The knee is thoroughly washed and the closure is done plan by plan.

No splinting is necessary.



Surgery under arthroscopy:

«Early minimally invasive « Ligamento-synthesis »

It is recommended in isolated posterior laxity and especially in fresh lesions. This internal fixation is then a simple gesture which does not add surgical trauma to accidental lesions.

The principles are the same as for open surgery. The particular points are :

- do not use an arthroscopic pump.
- if there is too much fluid leakage, which is rare, know how to give up and perform a short arthrotomy (monitoring the swelling of the leg ++).
- the tibial targeting device is introduced through a short vertical incision at the inner edge of the lower third of the patella; the tibial metal loop will exit through this same micro-incision.
- femoral tunnel: the femoral tunnel will be centred on the "isometric zone" already described.

The chosen point is marked by a 2 mm pin inserted percutaneously in the external line space at the outer edge of the patellar tendon.

This pin is given an oblique direction upwards, forwards and inwards. This pin is pushed by the motor through the internal condyle and out through the skin. A small counter-incision allows a protective tube to be slid over the pin and then a cannulated drill bit to be inserted over the pin.

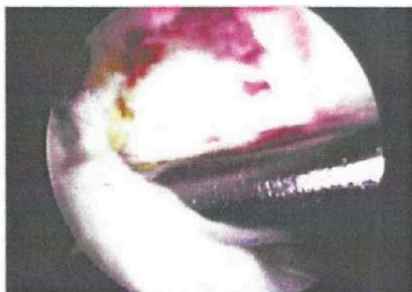
The arthroscopic control allows the drill to stop as soon as it passes the axial face of the condyle.

The drill is replaced by the threaded tube.

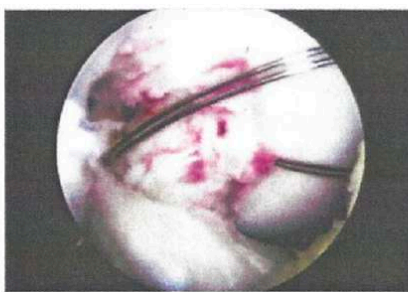A metal loop is pushed through it, which is recovered by a mini-clamp introduced through the internal incision which was used to pass the tibial sight and the corresponding metal loop. Through this same incision, the ligament is passed through the condyle and then through the tibia.

The arthroscope checks the correct positioning of the free fibres. Tensioning and fixation is done as in the open air.

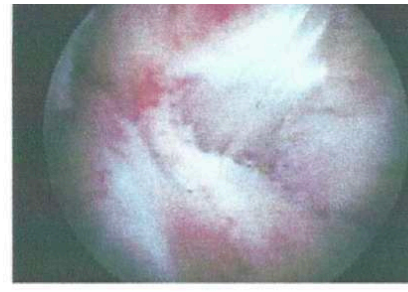
Aiming device at the inner edge



tibial and femoral wire loops



ligament in position



Surgical suites

The use of a synthetic implant (STIF - Vetlig Global TM) and the double fixation allows for complete and immediate mobilisation and full support.

A control radiograph of the face and profile immediately after the operation enables the centering of the stifle to be checked, the correct position of the screws and the absence of any element that could imply special precautions, such as a slit line on a screw for example.

The animal must be walked on a lead until the skin has completely healed.

Resumption of normal walking without lameness usually occurs within 15 days after the operation and normal activity during the following month.

A clinical examination and follow-up x-rays are desirable at 6 months and 1 year.

Simultaneous repair of anterior and posterior crossbones

In the case of a combined lesion of both crossbones, always start with the caudal crossbones plasty. In this case, the tension of the caudal crossbones cannot be adjusted when the cranial crossbones return to a normal position.

It is therefore prudent, in order to avoid hypercorrection and before final fixation of the ligaments, to ensure that the posterior edge of the tibial plateau corresponds to the posterior edge of the condyle on the stifle bent at 90°.

In case of doubt, and if possible, a profile intraoperatively should be taken to ensure this.

A line is drawn through the posterior edge of the condyle and parallel to the posterior edge of the tibial shaft. If the posterior edge of the tibial plateau is anterior to this line, the traction on the ligament should be released.

When the correct tension is achieved, the ligaments are fixed.

Under normal conditions, the cranial cruciate plasty can then be performed without the risk of "decentration" of the stifle.



VETLIG GLOBAL is a commercial trade mark owned by
STIF SAS

Société par actions simplifiées au capital de 375 530 €

Head quarter : 651 C Chemin de la Martourette

06530 Le Tignet

France

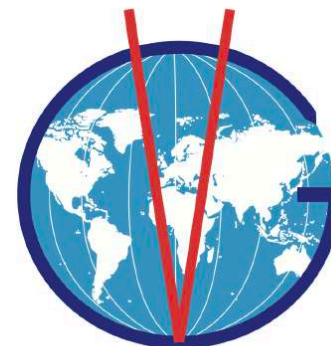RCS n° 522 917 939 - Grasse

SIRET : 522 917 939 00038

Intra-community VAT number FR 86 522 917 939

Code APE : 7219Z

VETLIG GLOBAL



Email : contact@vetlig-global.com

-

leo.brunel@vetlig-global.com

Tel : +33 (0)6 34 36 79 69

-

romain.gaucher@vetlig-global.com

Tel : +33 (0)6 84 09 60 67

STIF - Vetlig Global partners:

